Adult Crohn's Disease Treated With The Specific Carbohydrate Diet (SCD)

A Case Report Using Objective Markers Of Response with Exploratory Microbiome Analysis

Ali Arjomand, Ph.D., Modulla Health, Kirkland, Washington

INTRODUCTION

- There is growing interest in the role nutrition therapy plays in the induction and maintenance of remission in IBD
- The Specific Carbohydrate Diet (SCD) has been shown to induce remission in pediatric patients
- The response to SCD in adult IBD patients has not been adequately explored using objective markers of response
- Presented here is the first case report demonstrating successful treatment of moderate-to-severe adult Crohn's disease using SCD nutrition therapy, as assessed by objective markers of response

QUESTIONS

- Can SCD nutrition therapy induce clinical, endoscopic, radiologic, and histologic healing in adult IBD?
- What is the response time to SCD?
- Can SCD be implemented and maintained long term?
- How is the microbiome modulated by SCD?

CASE HISTORY

- 50-year-old male Crohn's disease patient, 2001 diagnosis
- Medical management consisted of:
  - > Mesalamine (1 g orally 4x/day for 6 months)
  - > Infliximab (300 mg IV/8 weeks for 5 years)
  - > Natalizumab (300 mg IV/4 weeks for 6 months)
  - > Adalimumab (40 mg sc/14 days for 7 years; then every 7 days for 1 year)
  - > Vedolizumab (300 mg IV/8 weeks for 1 year)
  - > Corticosteroids administered with adalimumab and vedolizumab over a continuous span of 8 years (prednisone 10-20 mg/day or budesonide 9 mg/day)
- Two resections of the terminal ileum (2003 and 2015)
- Annual ER and hospital admissions, renal failure, edema, embolism, severe malnutrition and albumin <1 g/dL
- Total Parenteral Nutrition (TPN) in 2008 and 2015

SCD INTERVENTION

- After losing response to all other treatments, the patient initiated and adhered to a strict SCD protocol[1]
- Nutrition supplements included iron, vitamin B_{12}
- Prednisone (40 mg/day) was initiated as a protective measure during diet transition, then tapered to 20 mg/day at month 3, and 0 mg at month 6, when the patient was off all medication for the first time in 17 years

Generalized Summary of the SCD Protocol

(-) Eliminate

All grains (wheat, rice, corn, oats, pseudo-grains)

Disaccharides (lactose, sucrose)

Polysaccharides (starchy vegetables, cellulose)

Processed foods (boxed and manufactured foods)

Additives, stabilizers, emulsifiers

(+) Add

Initial phase Broth, 24-hour fermented yogurt, ripe bananas, well-cooked carrots, chicken, eggs, honey

Over time, introduce ingredients (fish, meats, aged cheese, nut flours, nut butters, fruits, non-starchy vegetables, leafy greens, herbs, spices, nuts, seeds, legumes)

[1] Breaking the Vicious Cycle, Elaine Gottschall

RESULTS

IMPLEMENTATION & COMPLIANCE

The patient successfully adopted the SCD intervention, strictly adhering to SCD ingredients and expanding to a wider range of SCD ingredients over time.

Day 10 - The patient reported loss of all abdominal and lower back pain along with a 5 lb weight drop.

Month 3 - The patient reported 1-2 formed BM/day, increased energy and mobility, loss of joint pain and a stable weight. The patient initiated yoga 3x/week.

Stool was well-formed and of large mass.

Prednisone was tapered to 20 mg/day

Month 8 - The patient remained symptom-free and expanded SCD ingredients

Prednisone was tapered to 0 mg/day

Year 3 - The patient remains on a wide range of SCD ingredients

Scan to see examples of real world SCD foods

MRE Resolution of prior inflammation

Baseline

Fibrostenosing disease involving terminal and distal ileum extending approximately 14 cm in length.

A 3 cm portion of terminal ileum appears more fibrotic with active inflammation of adjacent distal ileum.

A 4 cm segment of jejunal inflammation within left upper quadrant.

No obstructive change.

12 Months

A 5 cm segment of fibrostenosing disease involving distal ileum with proximal dilatation.

Normal terminal ileal peristalsis. No generalized bowel obstruction.

Resolution of prior jejunal inflammation.

WEIGHT Initial loss and then stabilization

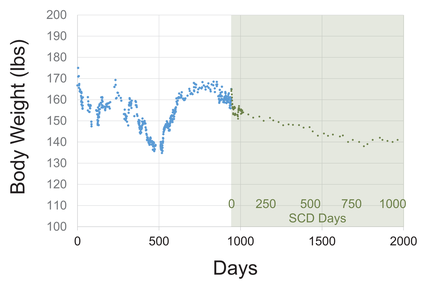

COLONOSCOPY

Histological mucosal healing at month 12

Baseline

Congestion, edema, erythema, exudates, friability, and ulceration in the terminal ileum compatible with Crohn's disease. (biopsy)

12 Months

Normal mucosa in the terminal ileum (biopsy).

Normal mucosa in the whole colon.

Stricture in the terminal ileum.

INFLAMMATORY MARKERS Rapid and sustained response to SCD nutrition therapy

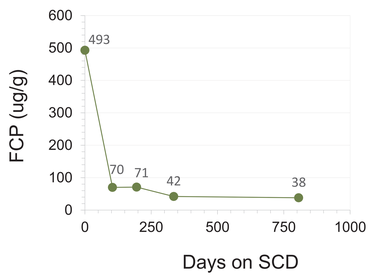

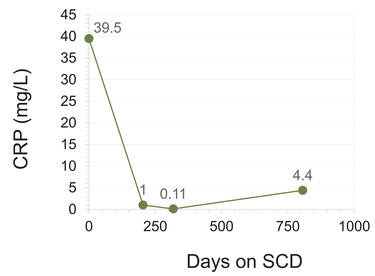

BIOANALYTICAL PANEL

Improved inflammatory, lipid, glucose, cardiovascular and nutritional markers

		Baseline	SCD
FCP	ug/g	**493**	**38**
CRP	mg/L	**38.5**	**4.4**
IL-6	pg/mL	**13.8**	**2.6**
IL-8	pg/mL	**8.0**	**3.5**
TNF-α	pg/mL	**1.2**	**0.8**
Systolic BP	mm Hg	**103**	**95**
Diastolic BP	mm Hg	**57**	**55**
Weight	lbs	**155**	**140**
Cholesterol	mg/dL	**114**	**109**
LDL	mg/dL	**47**	**40**
HDL	mg/dL	**36**	**39**
Triglycerides	mg/dL	**156**	**151**
Glucose	mg/dL	**82**	**81**
Insulin	uIU/mL	**6.1**	**3.6**
Hgb A1C	%	**5.1**	**4.5**
Vit D, 25-OH	ng/mL	**44.4**	**35.6**
Methylmalonic Acid	nmol/mL	**186**	**282**
Ferritin	ng/mL	**70**	**70**
Hematocrit	%	**39.2**	**37.9**
Hemoglobin	g/dL	**12.7**	**12.6**
Albumin	g/dL	**3.8**	**3.8**

All analytes at baseline and week 22 (FCP & CRP from week 104)

MICROBIOME

Low diversity and dominant phyla-level stability

	9 months pre-SCD	2 months pre-SCD	SCD month 10
Firmicutes	21%	41%	35%
Bacteroides	56%	41%	41%
Proteobacteria	5%	5%	4%
Verrucomicrobia	0%	0%	2%
Actinobacteria	1%	1%	1%
Fusobacteria	17%	12%	17%
Diversity Score	2.69	2.95	3.01

- Stool samples were collected 9 months and 2 months prior to SCD initiation and at month 10 of SCD
- The diversity score remained low across all collections although the patient was in clinical and biochemical remission at month 10
- Phyla-level microbiome analysis may not reveal changes occurring at the mucosal and epithelial interface
- Subtle, potentially impactful changes in the upper GI may be masked by large, more stable microbial mass in the lower GI, rendering phyla-level surveys of little use to individual monitoring

MICROBIOME

Short-term genus-level responsiveness

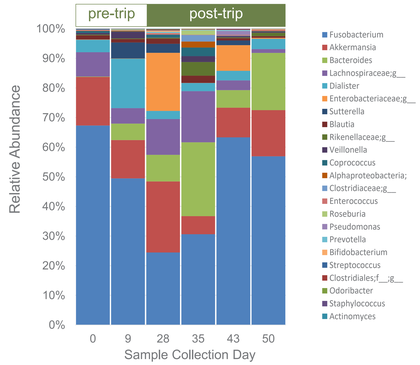

TRAVEL	18 day trip from Seattle to Hong Kong, Shanghai, Beijing
SAMPLING	2 pre-trip stool samples (Day 0 and 9); 4 post-trip stool samples (Day 28, 35, 43 and 50)
DIET	SCD was maintained throughout trip; only 1 exception (no homemade yogurt); no adverse events
DIVERSITY GAIN	Travel generated a dramatic increase in gut microbial diversity, likely due to geographical and people exposure
DIVERSITY LOSS UPON RETURN	Fusobacterium, Akkermansia and Bacteroides regained dominance within days with Bacteroides a new dominant resident at day 50.
GENUS LOSS AND RETURN	*Lactobacillus* was not detectable after travel but reappeared after travel return, possibly a short-term loss due to interruption of homemade yogurt consumption which resumed after travel return.

LOSS AND RETURN OF *LACTOBACILLUS* (SCD YOGURT?)

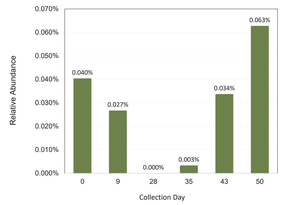

- *Lactobacillus* genus fell below reportable abundance during trip
- Coincided with pause in daily SCD yogurt consumption
- *Lactobacillus* relative abundance increased rapidly once daily yogurt consumption resumed after the trip

Firmicutes; Bacilli; Lactobacillales; Lactobacillaceae; Lactobacillus

CONCLUSIONS

- SCD nutrition therapy successfully induced clinical, endoscopic, radiologic, and histologic healing in an adult with moderate-to-severe Crohn's disease
- Clinical & biochemical response seen at 8 weeks, other markers at 12 months
- SCD was implemented and maintained over 3 years; the patient plans to continue SCD and is exploring re-introduction of other ingredients
- The mechanism of action of SCD is likely a targeted or wholesale modulation of the gut microbiome that results in normalized epithelia; fecal microbiome analysis may not reveal these intestinal microbiome changes in indviduals
- SCD nutrition therapy should be considered as an adjunct therapeutic option in IBD, and in certain cases, it can be the sole therapeutic modality when professionally supervised and tailored to meet the patient's clinical case, motivation and lifestyle constraints

Correspondence: ali@modullahealth.com @aliarjomand